

# Pulmonary scoring and pathological classification of lesions in lung and associated lymph nodes in slaughtered water buffaloes (*Bubalus bubalis*) in Northern Samar

Dina J. Ocaña<sup>\*1</sup>, Joseph S. Masangkay<sup>2</sup>, and Veronica A. Matawaran<sup>3</sup>

<sup>1</sup>Department of Paraclinical Sciences, College of Veterinary Medicine, University of Eastern Philippines, Catarman, Northern Samar, 6400, Philippines

<sup>2</sup>Department of Veterinary Paraclinical Sciences, College of Veterinary Medicine, University of the Philippines Los Baños, College Los Baños, Laguna, 4031, Philippines

<sup>3</sup>Vet Central Lab Philippines, Inc., City of San Juan, 1500, Metro Manila, Philippines

## ABSTRACT

The lungs and their associated lymph nodes, which jointly facilitate gas exchange and immune defense, are inherently vulnerable to respiratory problems, making pathological classification a reference point for disease incidence. In the province of Northern Samar, no data are available on the pathologic lesions affecting the lungs and associated lymph nodes in water buffaloes. The study was conducted in 280 water buffaloes of either sex and of different ages that were slaughtered at Catarman and San Roque slaughterhouses from June–September 2019. Pulmonary scoring revealed that most affected lungs had moderate lesions (Score 2; approximately 50% affected), predominantly mixed lesions. Gross and microscopic examination revealed pathologic lesions in the 105 (37.5%) water buffaloes. Grossly, mixed lesions characterized by the presence of two or more pulmonary pathological changes within the same lung were the most frequently observed lesion followed by adhesions and sequestrum while atelectasis and hydatid cyst lesions were observed least often indicating variable pathological processes. Histological examination showed that pneumonia was observed in 64 (22.86%), predominantly bronchopneumonia [42 animals (15%)] were the most commonly observed lesion. Older water buffaloes exhibited a higher lesion burden than younger animals and no significant differences were detected between sexes. A total of 197 lung-associated lymph nodes mainly bronchial and mediastinal lymph nodes were characterized by enlargement, congestion, and hemorrhage, with lymphoid hyperplasia frequently observed histologically. These

findings highlight the value of pulmonary scoring and lesion assessment in postmortem inspection in water buffaloes. They further emphasize the diagnostic significance of lesion-based surveillance in detecting subclinical respiratory diseases to enhance animal health monitoring, guide veterinary interventions, inform public health strategies and support meat safety.

## INTRODUCTION

In developing countries of Southeast Asia like the Philippines, ruminant animals, particularly water buffaloes, known locally as “carabao”, have an important economic role by providing draft power, meat, hides, and milk (Nanda and Nakao, 2003).

In the province of Northern Samar, agriculture, predominantly rice farming, is one of the main sources of economy wherein water buffaloes are the primary draft animal that provides necessary labor in the “payatak system” or “traditional farming” that still prevails in the province despite technological advances. In addition, the water buffaloes are also a popular meat source, and raising buffaloes is considered a profitable and sustainable enterprise.

Livestock diseases are problems of considerable importance to farmers. In tropical countries like the Philippines, they are major barriers in economic development and has great impacts not only in animal production but most importantly on the demand for animal-derived products particularly meat and milk. Respiratory diseases are a common health and economic problem affecting livestock such as water buffaloes which remain susceptible despite their wide range of environmental adaptability. These diseases involve a number of risk factors such as management practices,

\*Corresponding author

Email Address: [justiniane.dina11@gmail.com](mailto:justiniane.dina11@gmail.com)

Date received: 04 February 2026

Dates revised: 14 April 2026; 02 May 2026; 15 June 2026; 16 June 2026

Date accepted: 16 June 2026

DOI: <https://doi.org/10.54645/2026191OQG-91>

## KEYWORDS

lung, lymph node, pulmonary scoring, water buffalo

housing, nutrition, transport stress, and pathogen exposure and their etiology is considered multifactorial (Di Provvio et al., 2017; Taylor et al., 2010). The lung is the organ of respiration that is most exposed to different harmful agents because of its anatomical and histological peculiarities (Mekibib et al., 2019). Remarkably, bovine lung development is not over until twelve months of age, which predisposes them to respiratory diseases (Budras and Habel, 2011). On the other hand, lymph nodes are equally important as they function in filtering microorganisms and other undesirable substances. Also, they are involved in the immune system of the animal's body (McGavin and Zachary, 2012). Moreover, lymphatic circulation appears to be a vital component in lung biology in health and in disease (Baluk and McDonald, 2020).

Respiratory diseases in water buffaloes not only limit production but may also cause significant zoonotic risks. Several respiratory pathogens, such as *Mycobacterium bovis*, *Pasteurella multocida*, and *Mycoplasma spp.*, have zoonotic potential (Rahman et al., 2020; Cadmus et al., 2022), wherein some of these pathogens have been documented in the Philippines affecting buffaloes and cattle. Previous reports have documented outbreaks of respiratory-associated diseases in carabaos in Northern Samar, including hemorrhagic septicemia, highlighting the vulnerability of buffalo populations in the province and the importance of continued surveillance and pathological assessment (Molina et al., 1994).

The persistence of these pathogens not only raises concerns regarding occupational exposure among abattoir workers, farmers, and veterinarians but also has major implications for food safety and public health (Baluk and McDonald, 2020; OIE, 2023).

Considering that correct diagnosis is essential for the efficient treatment and/or prevention of respiratory problems, pathological examinations at necropsy are extremely valuable to make a rapid, presumptive diagnosis as well as to intensify further laboratory investigations (Ozturk et al., 2019).

Furthermore, postmortem examination of the lungs at slaughter allows "scoring" of lung pathology which is essential in the assessment of the health status of animal populations (Snowder et al., 2006; Yates, 2020). Further, it also evaluates the efficacy of the therapeutic and/or measures undertaken and plays a pivotal role in providing valuable information and a reference point for estimating disease occurrence/incidence. Additionally, slaughterhouses provide an opportunity for the identification and classification of pathological lesions which can contribute to the understanding of livestock diseases at slaughter and provide a cost-effective means of livestock health assessment at the population level, particularly in regions where diagnostic resources are limited (Alton et al., 2019).

There is a gap in available information on the pathological lesions in the lungs and their associated lymph nodes in water buffaloes particularly in the province of Northern Samar. Therefore, for better understanding of the pulmonary diseases affecting buffaloes, this study was conducted to provide information and establish baseline data on pulmonary lesions of water buffaloes in the province to strengthen local disease monitoring for improved animal and public health outcomes.

## MATERIALS AND METHODS

All procedures for sample collection were approved by the Institutional Animal Care and Use Committee (IACUC) of the University of Eastern Philippines with Protocol No. 2020-0002.

### Location

The study was conducted on 280 water buffaloes of either sex and of different ages that were slaughtered in Catarman and San Roque

slaughterhouses in the province of Northern Samar, Philippines during the period from June–September 2019.

### Sampling Method and Processing

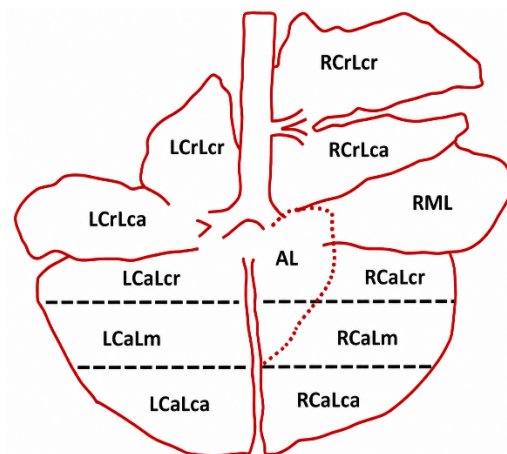
Non-probability sampling with purposive inclusion of the study animals was employed in this study during the period from June–September 2019. A total of 280 water buffaloes were subjected to evaluation of any pathological lesions in the lungs and associated lymph nodes.

### Ante-mortem Examination

Prior to slaughter, information on the animals regarding the origin, owner, sex, and age was documented based on the available records from the slaughterhouses. Likewise, body condition was noted and animals were physically examined for any signs of respiratory abnormalities which was done while the animal was at rest and in motion following FAO (1994) guidelines.

### Pulmonary Scoring

In this study, pulmonary scoring was performed in 280 lungs to assess the presence of lung lesions. Of the 280 animals evaluated, 105 animals showed pulmonary lesions, while 175 animals showed no observable lesions. Evaluation was done directly in the slaughterhouse. Initially, each lung was subdivided into 11 areas (Figure 1) which was adopted from the method applied by Di Provvio et al., (2017) to facilitate standardized lesion identification and data recording.



**Figure 1:** Diagram showing the area subdivision of bovine lung for lesion identification and scoring.

Abbreviation	Description
LCrLcr - left cranial lobe cranial	RCrLcr - right cranial lobe cranial
LCrLca - left cranial lobe caudal	RCrLca - right cranial lobe caudal
LCaLcr - left caudal lobe cranial	RML - right middle lobe
LCaLm - left caudal lobe middle	RCaLcr - right caudal lobe cranial
LCaLca - left caudal lobe caudal	RCaLm - right caudal lobe middle
AL - accessory lobe	RCaLca - right caudal lobe caudal

Each caudal lobe is further subdivided into caudal, middle, and cranial bounded by black dashed line.

During the evaluation, each lung was first positioned properly and visually examined on both sides, particularly the cranial and ventral portions according to the assessment method described by previous researchers (Table 1).

Lung score was based on the severity and extent of lesions in which the presence of a lesion was assigned 1 point per affected area of the lung; hence, score ranged between 0 and 11 points. All the scores generated per lung were summed up and lung scores were assigned using a 4-point scale with score 0 for absence of lesion or healthy lung, score 1 for minimal lesions (1–3 points), score 2 for moderate lesions (4–6 points) and score 3 for severe lesions (7–11 points) (Table 1).

**Table 1:** The scoring system adopted for the evaluation of lung lesions in water buffalo.

Scale/Score	Description (Lung Score Range)	Lesion Severity	Approximate Lung Involvement (%)	References
0	Absence of lesion	No lesion	0%	Leruste et al. (2021)
1	1-3 points	Mild/Minimal	~25%	Di Provvido et al. (2017)
2	4-6 points	Moderate	~50%	Magrin et al. (2012)
3	7-11 points	Severe	~75%	

**Gross Pathological Examination**

Detailed post-mortem observations were made at the slaughterhouse. One hundred five (105) of the 280 water buffaloes were found to have visible lung lesions and a total of one hundred ninety-seven (197) associated lymph nodes, mainly from bronchial and mediastinal lymph nodes were documented to have appreciable lesions during the gross examination. The assessment was performed before the routine veterinary inspection to include lungs that would have been cut or discarded during the inspection. Examination was done using the routine methods of visualization, palpation, and incisions when required and all observations were recorded and documented accordingly.

**Collection of Samples**

Lung and associated lymph node samples 1–3 cm thick were collected and fixed in 10% neutral buffered formalin for histopathological processing and examination. The collected representative tissue samples were processed, paraffin-embedded, sectioned, and prepared as histological slides following standard protocols at the Department of Veterinary Paraclinical Sciences (DVPS) in the College of Veterinary Medicine, University of the Philippines, Los Baños and at Vet Central Laboratory.

**Histopathological Examination**

Prepared histological sections were stained with hematoxylin and eosin (H&E) and examined under light microscopy for lesion identification. All findings were submitted for review by a qualified veterinary pathologist.

**Classification of Lesions**

Gross and microscopic lesions were identified and classified based on their morphologic characteristics. Notably, both evaluations were performed on the same lung samples, consequently, lesions identified on gross examination could also exhibit corresponding microscopic changes. Hence, the frequencies reported for gross and

microscopic lesions represent overlapping observations and should not be interpreted as independent totals. All the findings are consistently expressed as number (No.) and percentage (%) (Table 3). Likewise, lung lesions observed in slaughtered water buffaloes were compared according to sex and age of the animals.

**Analysis and Presentation of Data**

Data were analyzed using descriptive statistics, including frequencies and percentages. Results were summarized and presented in tables and figures.

**RESULTS AND DISCUSSION****Overview**

In this study, a total of 105 (37.5%) out of two hundred eighty (280) slaughtered water buffaloes of both sexes and different ages showed various lesions of varying distribution and severity in the lungs and associated lymph nodes. Whereas, no lesions were observed in the remaining 175 (62.5%) slaughtered water buffaloes during the study period.

**Pulmonary Scoring**

Lung scoring showed varying degrees of pathology (Table 2) in which the majority of lung lesions detected were predominantly of mild to moderate severity and were commonly observed in much older animals. Some of these affected water buffaloes did not show evident respiratory signs on ante-mortem examination, indicating the limited diagnostic capacity of clinical examination and supporting the value of slaughterhouse-based lung scoring. It allows data collection within a reasonable time and at lower cost and labor requirements, while providing valuable information on lesion incidence which can be reflective of subclinical disease status definitely not detected in live animals.

**Table 2:** Pulmonary lesion scores in water buffaloes.

Scale/Score	Animals Affected (N, %)	Lung Score Range	Approximate Lung Involvement (%)	Lesion Severity
0	175 (62.5%)	0	0%	No Lesion
1	39 (13.93%)	1–3	~25%	Mild
2	52 (18.57%)	4–6	~50%	Moderate
3	14 (5%)	7–11	~75%	Severe

**Pulmonary Pathological Findings**

The findings of the study revealed a 37.5% overall incidence of lung lesions (Table 3) in slaughtered water buffaloes based on gross and microscopic examination. These lesions were classified

morphologically according to the gross and histopathological findings.

Grossly, mixed pulmonary lesions [35 (12.50%)] commonly consisted of pulmonary consolidation, emphysema, atelectasis,

pleural adhesions, fibrin deposition, edema, and hemorrhages were the most frequently observed findings while hydatid cysts and atelectasis 1(0.36%) were the least frequent findings. Histopathologic findings were characterized into pneumonic lesions 64(22.86%), circulatory disturbances 6(5.71%), abnormalities in inflation 22(7.86%), bronchitis and bronchiolitis 2(0.71%), and parasitic condition 1(0.36%). Notably, the same patterns of lesion incidence have been documented in slaughterhouse-based studies in ruminant populations, showing the importance of slaughterhouse surveillance as a tool in animal health monitoring.

This study commonly documented pneumonic lesions wherein, bronchopneumonia was noted in 42(15%) of the examined lungs in which 10(3.50%) and 32(11.43%) were further characterized as suppurative and fibrinous bronchopneumonia, respectively. Observe lesions were exudative airway obstructions and cranioventral consolidation, primarily affecting the cranial and middle lobes exhibiting red to gray hepatization, consistent with

classic descriptions in bovine pulmonary pathology (Machhaliya et al., 2015; Carlton and McGavin, 1995). Also seen are lesions such as adhesions, marbled appearance, distended interlobular septa due to fibrosis (Fig. 2A) and fibrinous exudates in alveoli and airways infiltrated with mononuclear cells (Fig. 2B) and sequestrum (Fig. 2C) which supports chronicity of infection, a common sequela found in animals that survived an acute episode of fibrinous bronchopneumonia (Carlton and McGavin, 1995). In addition, it is a common pathological finding in Contagious Bovine Pleuropneumonia (CBPP), a disease of cattle and water buffaloes caused by *Mycoplasma mycoides subsp. mycoides* (Di Provvido et al., 2017). Moreover, aside from its respiratory anatomical peculiarities, observed lesions could be possibly attributed to a wide variety of infections with bacterial agents which include *Pasteurella spp.*, *Klebsiella pneumoniae*, septicemic *E. coli*, *Mycobacteria*, *Mycoplasma* and mycotic infections such as those caused by toxins of *aspergilli* (McGavin and Zachary, 2012; Camer et al., 2018, Molina et al, 1994).

**Table 3:** Incidence of gross and microscopic lesions in lungs in slaughtered water buffaloes in Northern Samar.

Organ	Gross Lesion	Incidence (N=280)		Microscopic Lesion	Incidence (N=280)	
		No.	%		No.	%
Lung				<b>Pneumonia</b>	<b>64</b>	<b>22.86%</b>
				Bronchopneumonia	42	15.00%
	Consolidation	7	2.50%	Suppurative	10	3.57%
	Emphysema	17	6.07%	Fibrinous	32	11.43%
	Atelectasis	1	0.36%	Interstitial Pneumonia	21	7.50%
				Parasitic Pneumonia	1	0.36%
				<b>Circulatory Disturbances</b>	<b>16</b>	<b>5.71%</b>
	Hemorrhage & Congestion	5	1.79%	Congestion	4	1.43%
	Edema	3	1.07%	Hemorrhage	6	2.14%
	Sequestrum	13	4.64%	Pulmonary edema	6	2.14%
	Adhesions	21	7.50%	<b>Abnormalities in Inflation</b>	<b>22</b>	<b>7.86%</b>
	Hydatid cysts	1	0.36%	Emphysema	17	6.07%
	Abscess	2	0.71%	Atelectasis	5	1.79%
	Mixed (two or more) lesions	35	12.50%	<b>Bronchitis &amp; Bronchiolitis</b>	<b>2</b>	<b>0.71%</b>
				<b>Parasitic condition</b>	<b>1</b>	<b>0.36%</b>
				Hydatid cysts	1	0.36%
	<b>Total</b>		<b>105</b>	<b>37.50%</b>		<b>105</b>

This study identified 21(7.50%) cases of interstitial pneumonia. Affected lungs failed to collapse and were pale, heavy with visible rib imprints, somewhat rubbery in texture and meaty appearance with diffuse distribution. Furthermore, lobules are clearly accentuated by interlobular septa that are distended with gas bubbles and edema fluid that freely exuded from the cut surface (Fig 2E). On histopathologic examination, the alveolar septa were thickened, congested, and infiltrated with mononuclear cells mainly lymphocytes with evident peribronchiolar lymphoid hyperplasia. Most of the findings reflected the three important features of interstitial pneumonia (IP) specified by Carlton and McGavin, (1995) and is consistent with the findings of Panciera and Confer (2010).

The high incidence of pneumonic lesions particularly fibrinous and suppurative bronchopneumonia, pleural adhesions and interlobular septal distension likely reflects post-infectious sequelae in animals that survived previous systemic or respiratory infections. This finding is notable given the documented history of hemorrhagic septicemia outbreaks among carabaos in Northern Samar, highlighting the need for continuous and regular implementation of anti-hemorrhagic septicemia vaccination programs (Molina et al., 1994). The presence of chronic pulmonary lesions such as sequestrum formation, fibrosis, and mononuclear cell infiltration

further supports the evidence of previous acute inflammatory insults consistent with the pathogenesis of hemorrhagic septicemia. Furthermore, the observed interstitial pneumonia and lymphoid hyperplasia may indicate immune-mediated or recovery-stage changes following severe septicemic infections. Notably, the documented history of hemorrhagic septicemia underscores the role of acute septicemic diseases in determining the pulmonary lesion profile observed at slaughter and reinforces the value of slaughterhouse-based surveillance for retrospectively evaluating long-term pathological impact of infectious disease outbreaks in carabao populations.

An infrequent case of parasitic pneumonia was documented in this study with an incidence of 1(0.36%). The affected lung appeared swollen with sparse atelectasis and emphysema. A thin white, slender worm admixed with frothy fluid was seen in a cut airway possibly identified as *D. viviparus*, the common lungworm infecting cattle and buffalos. This gross observation was validated microscopically by the presence of nematode within the lumen of the bronchiole (Fig. 2D) which was observed from the same lung sample where most of the areas revealed ruptured alveolar septa and distended alveoli while few areas were filled with inflammatory infiltrates mainly lymphocytes and eosinophils in addition to peribronchiolar lymphoid hyperplasia (Fig. 2F).

Likewise, a solitary case 1(0.36%) of sterile hydatid cyst on the surface of the dorsal portion of the right cranial lobe was observed. While hydatid cyst has little clinical significance in the affected animal, it is an important cause of zoonotic disease and economic loss due to carcass condemnation (Carlton and McGavin, 1995; OIE, 2023).

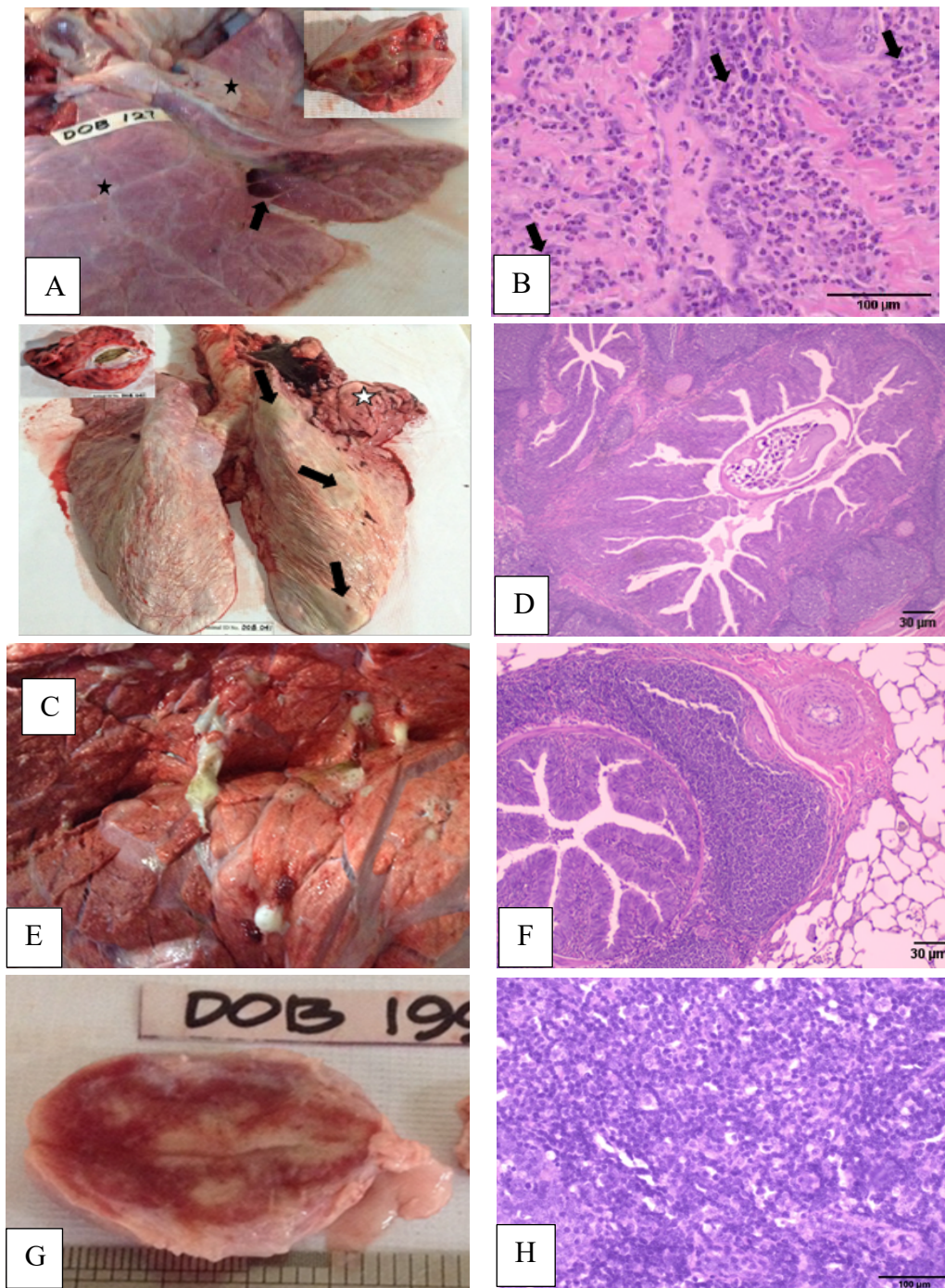
### Lung Associated Lymph Nodes Pathological Findings

A total of 197 lung-associated lymph nodes showed lesions on examination, mainly in the bronchial and mediastinal lymph nodes. The lesions included enlargement, congestion, hemorrhages, hyperemia, and frequent lymphoid follicular hyperplasia (Fig.2G&H). These types of lesions observed in lymph nodes are suggestive of a response to persistent respiratory challenges and

granulomatous processes, reflecting the critical role of lymphoid tissues in detection and containment of pulmonary pathogens (Baluk & McDonald, 2020).

### Classification based on age and sex

Gross and histopathologic lesions were observed in the lungs of 67(63.81%) males and 38(36.19%) females slaughtered water buffaloes. The findings reflect the demographic composition of the slaughter population rather than inherent biological susceptibility as female water buffaloes are usually retained for breeding. Older slaughtered water buffaloes were the animals most frequently observed with lung lesions.



**Figure 2:** Lung and Associated Lymph Node Pathological Lesions. (A) Section showing adhesions (arrow), marbled appearance (inset), distended interlobular septa (star); (B) Section showing fibrinous exudate in alveoli and airways infiltrated with mononuclear cells (H&E); (C) A massive sequestrum (star) in the middle lobe of right lung filled with necrotic parenchyma encapsulated by dense fibrous tissue (inset) and multifocal abscess (arrows) on the pleural surface of the right lung; (D) Section showing nematode inside the bronchiole; (E) Cut section of the lung showing white frothy fluid exuding from the airways in edematous lung; (F) Section showing peribronchiolar lymphoid hyperplasia (H&E); (G) Bronchial LN showing enlargement & severe hyperemia; (H) Section showing lymphoid hyperplasia (H&E).

## CONCLUSION AND RECOMMENDATION

The results observed in this study showed the spectrum of pathological lesions in the lungs and their associated lymph nodes in slaughtered water buffaloes, with pneumonic conditions, particularly bronchopneumonia, as the predominant findings. The gross and histopathological findings showed both acute and chronic disease processes demonstrating persistent pulmonary insults. While hydatid cysts and parasitic pneumonia were rarely observed, these findings remain significant due to public health and economic implications.

Lesions observed in lung-associated lymph nodes such as lymphoid hyperplasia, support persistent respiratory challenges and ongoing immune stimulation in these animals. The age- and sex-based distribution likely reflects slaughter demographics rather than biological susceptibility, with a higher proportion of lesions observed in older and male buffaloes, likely due to breeding purposes and management.

Results showed that post-mortem examination and lesion scoring at slaughter are valuable, as several lesions can be reflective of subclinical disease status not easily detected in live animals specifically those regarded as potential zoonotic diseases. In addition, slaughterhouse surveillance is a practical and cost-effective approach for monitoring and identifying respiratory problems, prevalent disease patterns and generating epidemiological data in food animals. With this approach coupled with disease prevention and control strategies, may significantly contribute to safeguarding public health, improving animal health, and reducing economic losses in the water buffalo industry.

Therefore, antemortem and postmortem examinations, including ancillary tests, should be routinely implemented in slaughterhouses as part of integrated One Health monitoring systems. These measures can generate epidemiological data, support early identification of zoonotic and economically important respiratory diseases, improve disease control and prevention, and help ensure safe meat for human consumption.

## ACKNOWLEDGMENT

The authors gratefully express their appreciation to the DOST–NRCP Career Mentoring Program in the preparation of this manuscript. Sincere acknowledgment is due to LGUs of Catarman and San Roque, Northern Samar; the Carabao owners who permitted data collection and sampling; the institutional support of the University of Eastern Philippines and the University of the Philippines Los Baños; and the CHED K to 12 Transition Scholarship Program for funding. The funder had no role in the study design, data collection, and analysis, decision to publish, or preparation of the manuscript.

## CONFLICT OF INTEREST

The authors declare no competing or conflicting interests.

## CONTRIBUTIONS OF INDIVIDUAL AUTHORS

Conceptualization, DJO, and VAM; Methodology, DJO and VAM, Investigation, DJO; Writing – Original draft, DJO; Writing – Review and Editing, DJO, VAM and JSM; Funding Acquisition, DJO; Resources, DJO; Supervision, DJO, VAM, and JSM; Project Administration, DJO

## REFERENCES

- Alton GD, Pearl DL, Bateman, KG, McNab WB, & Berke O. Abattoir surveillance for food animal diseases in developing regions. *Preventive Veterinary Medicine*. 2019 July 165, 45–52.
- Baluk P & McDonald DM. The lymphatic system in disease processes. *Annual Review of Pathology*. 2020 Jan 15, 97–122.
- Budras HD, Habel RE. *Bovine Anatomy*, <https://books.google.com.ph/book?2011> ISBN=3842683596.
- Cadmus S, Oluwafemi OO, Odetokun AA, Gibson AJA, Akinseye SO, Cadmus TM. 2022. Bovine tuberculosis and public health risks in developing countries. *One Health Outlook*. 2022 April; 4:9. Published April 2022.
- Camer GA, Carpio JM, Ocaña DJ, Doncillo JS, Paredes JT, Orejudos AR, Gajutos AB, Amit RA, Masangkay JS. Clinicopathological characterizations in select food Animals in Northern Samar. *Journal of Agriculture and Technology Management*. 2018 21(1) 35-38. <https://rb.gy/wtc7b3>
- Carlton WW, McGavin MD. *Thomson's Special Veterinary Pathology*. 1995; 2nd ed. St. Louis, Missouri, USA: Mosby-Year Book.
- Di Provvido A, Di Teodoro G, Muuka G, Marruchella G, Scacchia M. Lung Lesion Score System in Cattle: Proposal for Contagious Bovine Pleuropneumonia. *Trop Ani Health Prod*. 2017 Sep; 50(1), 223–228. doi:10.1007/s11250-017-1409-2
- Food and Agriculture Organization of the United Nations (FAO). *Manual on meat inspection procedures*. 1994. FAO, Rome, Italy.
- Leruste H, Brscic M, Heutinck LFM, Visser EK, Wolthuis-Fillerup M, Bokkers EAM, Stockhofe-Zurwieden, Cozzi NG, Gottardo F, Lensink BJ, Reenen CG Van., 2012. The relationship between clinical signs of respiratory system disorders and lung lesions at slaughter in veal calves. *Preventive Veterinary Medicine*. 2012 Jun; 105 (1-2):93-100. doi: 10.1016/j.prevetmed.2012.01.015.
- Machhaliya MH, Patel BJ, Joshi DV, Raval SH, Patel JG. Pathomorphological studies on spontaneously occurring pulmonary lesions in buffaloes (*Bubalus bubalis*). *Ruminant Science*. 2015 March; 4(1):51–53.
- Margin L, Brscic M, Lora I, Prevedello P, Contiero B, Cozzi G, Gottardo F., 2021. Assessment of rumen mucosa, lung, and liver lesions at slaughter as benchmarking tool for the improvement of finishing beef cattle health and welfare. *Front. Vet. Sci*. 2021 Jan; 7:622837. doi:10.3389/fvets.2020.622837.
- McGavin MD, Zachary JF. *Pathologic Basis of Veterinary Disease*. 2012; 5th ed. St. Louis, Missouri, USA: Elsevier Mosby.
- Mekibib B, Mikir T, Fekadu A, Abebe R., 2019. Prevalence of pneumonia in sheep and goats at Elfora Bishoftu export abattoir, Ethiopia: a pathological investigation. *Journal of Veterinary Medicine*. 2019:5169040. doi:10.1155/2019/5169040.
- Molina HA, Camer G, Padilla MA. Outbreak of hemorrhagic septicemia among carabaos in Northern Samar [Philippines]. *Philippine Journal of Veterinary Medicine*, 1994 31(1) 27-31.
- Nanda AS, Nakao T. Role of buffalo in the socioeconomic development of rural Asia. *Animal Science Journal*, 2003 74, 443–455.

- Ozturk D, Ozturk KG, Aydin AG, Yilmaz HG. 2019. Gross and histopathological characterization of pulmonary lesions in cattle. *Ankara University Veterinary Journal*. 2019 Aug;66(4):375–382.
- Panciera RJ, Confer AW. Pathogenesis and pathology of bovine pneumonia. *Veterinary Clinics of North America: Food Animal Practice*. 2010 Jul; 26(2):191–214.
- Rahman MT, Sobur MA, Islam MS, Ievy S, Hossain MJ, El Zowalaty ME, Rahman AT, Ashour HM. 2020. Zoonotic diseases: etiology, impact, and control. *Microorganisms* 2020 Sep; 8(9):1405.
- Snowder GD, Van Vleck LD, Cundiff LV, Bennett GL. Bovine respiratory disease in feedlot cattle: Environmental, genetic, and economic factors. *Journal of Animal Science*. 2006 Aug; 84(8):1999–2008.
- Taylor JD, Fulton RW, Lehenbauer TW, Step DL, Confer AW. The Epidemiology of Bovine Respiratory Disease: What is the evidence for predisposing factors? *The Canadian Veterinary Journal*, 2010 51(10), 1095-1102.
- World Organization for Animal Health (OIE). *One Health and zoonotic disease control framework*. 2023 Paris: OIE.
- Yates WDG. The pathogenesis of pneumonia in cattle. *Veterinary Pathology*. 2020 57(3), 443–457.